

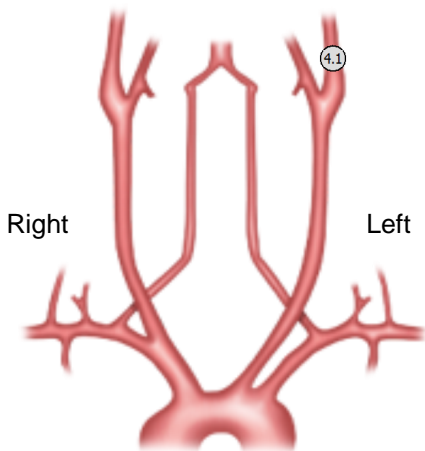


Visualize: Vascular Report

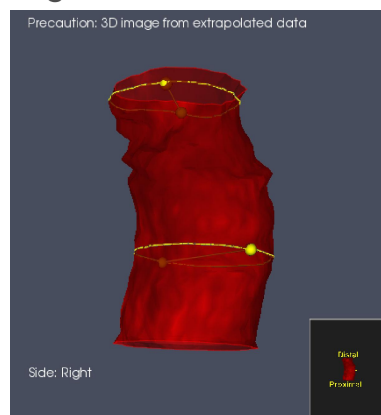
General Hospital - Main Street, USA

Patient Name	MEDI-CV-MORPH LS	Exam Date	3/19/2010
MRN	1-014	Accession Number	-
DOB (Age)	-	Exam Type	76377 3D Reconstruction
Sex	-	Report Author	Technologist, RVT
Date Reported	2/10/2012		

4.1: visible plaque

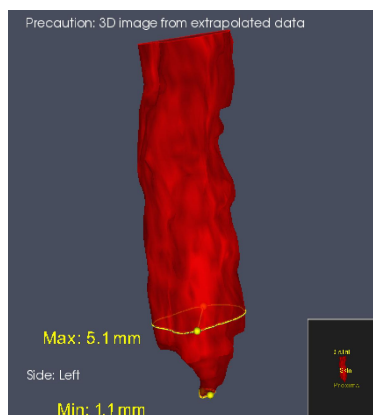


Right ICA



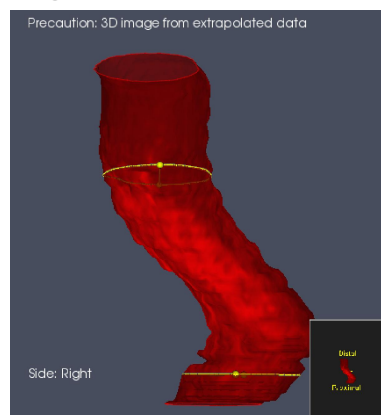
Luminal diameter: Min 4.1, Max 6.2 mm
Luminal reduction: 34%

Left ICA



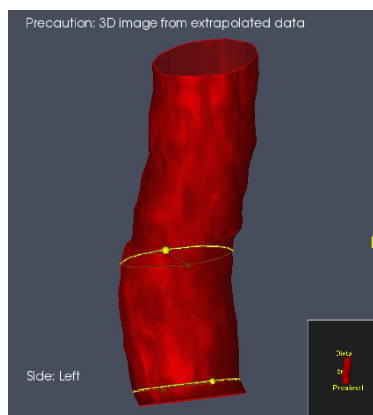Luminal diameter: Min 1.1, Max 5.1 mm
Luminal reduction: 79%

Right CCA



Luminal diameter: Min 6.4, Max 7.6 mm
Luminal reduction: 16%

Left CCA



Luminal diameter: Min 5.8, Max 7.5 mm
Luminal reduction: 23%